

See discussions, stats, and author profiles for this publication at: <https://www.researchgate.net/publication/365901627>

Shallow Water Blackout (Hypoxic Blackout)–Induced Drowning: An Autopsy Report of Two Cases

Article · November 2022

DOI: 10.7580/kjlm.2022.46.4.122

CITATIONS

0

READS

18

6 authors, including:



[Sanghan Lee](#)

Ministry of National Defence Criminal Investigation Command

26 PUBLICATIONS 114 CITATIONS

[SEE PROFILE](#)

Some of the authors of this publication are also working on these related projects:



An unusual death due to burst of the dump truck tire [View project](#)



Shallow Water Blackout (Hypoxic Blackout)–Induced Drowning: An Autopsy Report of Two Cases

Sangjoon Choi, SangHan Lee,
Yo Han Jeon, Ji Hyun Park,
Jong Kyu Lee, Nam Seok Yeo

*Department of Forensic Medicine,
Defense Institute of Forensic Science,
Criminal Investigation Command,
Ministry of National Defense, Seoul,
Korea*

Received: August 19, 2022
Revised: October 24, 2022
Accepted: November 7, 2022

Correspondence to

SangHan Lee
Department of Forensic Medicine,
Defense Institute of Forensic
Science, Criminal Investigation
Command, Ministry of National
Defense, 22 Itaewon-ro, Yongsan-gu,
Seoul 04383, Korea
Tel: +82-2-748-1960
Fax: +82-2-748-1909
E-mail: sanghan111@gmail.com

Shallow water blackout (SWB) is defined as loss of consciousness due to hypoxia during underwater swimming or breath-holding, usually in shallow waters. To date, no cases of SWB-induced drowning have been reported in the Republic of Korea. Here, we report two cases of SWB, followed by drowning, with autopsy findings. Two men, aged 20 (case 1) and 25 (case 2) years, suddenly lost their consciousness during underwater swimming and escape training, respectively. Postmortem examination revealed foamy fluid within trachea and bronchus, pulmonary edema, and sphenoid sinus fluid, which are commonly observed findings in drowning cases. None of the organs in either case showed pathologic alterations, except for hypoplastic coronary artery disease incidentally found in case 2. Pathologists should be aware of this distinct pathologic entity to avoid misdiagnosing the cause or manner of death.

Key Words: Autopsy; Unconsciousness; Drowning

Introduction

Shallow water blackout (SWB) refers to a sudden loss of consciousness caused by cerebral hypoxia during underwater swimming or breath-holding [1]. People who faint because of SWB can drown unless rescued immediately. SWB is commonly preceded by hyperventilation before breath-holding. Hyperventilation lowers the partial pressure of carbon dioxide in blood and diminishes the desire to breathe [2,3]. During underwater swimming or breath-holding, oxygen levels drop to the critical point of hypoxic

blackout, but the diver feels no urgent need to breathe, leading to sudden unconsciousness [2].

In the United States, an official website is being operated for the education and prevention of SWB [4]. However, the definition, etiology, and pathophysiology of SWB are poorly understood among Koreans. Therefore, drowning caused by SWB is not well known, even to experienced forensic pathologists.

We recently encountered two cases of SWB that resulted from drowning. To the best of our knowledge, no such case has been reported before in the Republic of Korea. Here, we provide the autopsy findings of SWB-

induced drowning and report the related circumstances. We also describe the points of caution when writing an autopsy report of SWB-induced drowning.

Case Report

1. Case 1

The deceased person was a previously healthy 20-year-old marine corps soldier who was preparing for practical examination for the military. He was practicing underwater swimming in a 13-m-long and 1.3-m-deep swimming lane, and his movements were captured on a closed-circuit television camera. He hyperventilated for 70 seconds before his last swimming stroke. At the time, he had finished two rounds of underwater swimming (distance: 52 m; time taken: 53 seconds). He subsequently collapsed backwards and lost consciousness. After collapse, seizure-like movements of his head, arms, and legs were observed intermittently for several minutes. He was not surrounded by any witness and was discovered 25 minutes after drowning. Cardiopulmonary resuscitation was performed but failed to revive him. Autopsy was performed 24 hours after his death. He was well-nourished and showed no injuries on external examination. Common autopsy findings of drowning, including edematous lungs, froth along the trachea and bronchus (Fig. 1A), fluid in the

sphenoid sinuses, petromastoid hemorrhage, and liquid in the duodenum, were observed. The cause and manner of death were determined as drowning and accident, respectively.

2. Case 2

The deceased person was a previously healthy 25-year-old male navy officer. He was conducting underwater escape training in a 10-m-deep pool. He completed ladder climbing and was performing diving bell escape training. During the training, he suddenly switched his turn with the person in front of him, escaped from the 7-m-deep diving pool, and ascended to the surface. Immediately afterwards, he lost consciousness and sunk to the bottom of the bell. He was rescued by security guards, provided with cardiopulmonary resuscitation, which failed, and brought to the emergency room. Autopsy was performed 24 hours after his death. Gross findings were severe pulmonary edema (Fig. 1B), fluid in the sphenoid sinus, and petromastoid hemorrhage. As in case 1, the cause and manner of death were determined as drowning and accident, respectively.

Discussion

Most cases of SWB occur in waters shallower than 15 ft (5 m) but can occur in deeper waters as well [1].

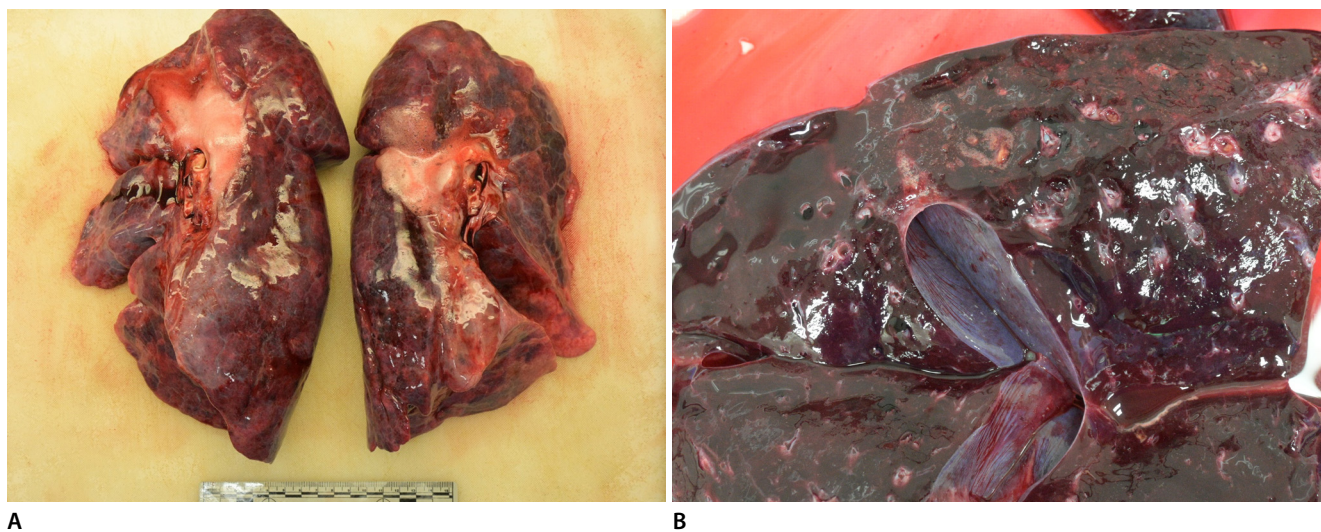


Fig. 1. Representative autopsy findings of shallow water blackout-induced drowning. (A) Case 1: Frothy fluid within the bronchus. (B) Case 2: Lung section showing edematous fluid and foams.

SWB can occur in anyone who holds their breath while swimming or practicing breath-holding underwater but usually occurs in experienced, young male swimmers [5]. A case series from the United States summarized a total of 16 cases from 1988 to 2011 [5]. The people included 13 (81%) men and three (19%) women, with 15 (94%) people under the age of 25 years and one (6%) person over the age of 25 years. While nine (56%) people were good or advanced swimmers, seven (44%) people were not. SWB frequently occurred during hypoxia training (7/15, 44%) or static apnea (i.e., breath-holding games; 6/15, 38%). Four of the 16 (25%) people fatally drowned, three (75%) of whom were in the military. The monthly medical surveillance report from the United States Armed Forces shows a total of 71 fatal drowning cases from 2008 to 2014 from the United States Marine Corps and Navy, 17 (24%) of which occurred on duty [1,6]. Therefore, the dangers of SWB should be noted even for the experienced and fit swimmers to reduce avoidable deaths [7]. Since SWB occurs without any warning sign of onset, people who perform hypoxia training to improve their ability to swim long distances underwater should be trained under strict supervision with lifeguards.

The individuals in the two present cases showed typical clinical features of drowning caused by SWB in that they suddenly lost consciousness during underwater swimming and/or training. They were advanced swimmers and on military service for the marine corps and navy. In the macroscopic analysis, neither case exhibited features other than typical findings of drowning. Case 2 showed incidental hypoplastic coronary artery disease (HCAD) and was previously reported in the *Korean Journal of Legal Medicine* as a forensic figure [8]. The criteria for death from HCAD are as follows: markedly diminutive coronary artery or arteries, absence of compensatory collateral circulatory vessels, microscopic evidence of cardiac ischemia (acute or chronic), and exclusion of other causes of death [9]. In case 2, the heart had no collateral circulatory vessel, and microscopic examination revealed no evidence of myocardial ischemia. The circumstance at the time of the accident strongly suggested a diagnosis of drowning. Therefore, sudden cardiac death associated with HCAD was excluded as a cause of death.

Forensic pathologists should be aware of this rare but distinct entity when they encounter drowning cases, particularly when the victims are good swimmers. Less experienced pathologists may not understand the phenomenon in which good swimmers lose consciousness while swimming underwater and misdiagnose the cause and manner of death. A possible error is determining the cause of death as “sudden cardiac death” and documenting the manner of death as a “natural death by disease.” However, SWB should not be regarded as natural death as its pathogenesis is not associated with underlying disease. Additionally, SWB-induced drowning differs from traditional accidental drowning because it is preventable by adequate education and safety training. Forensic pathologists should determine the cause and manner of death after a comprehensive analysis of the autopsy findings and drowning circumstances of the deceased.

ORCID: Sangjoon Choi: <https://orcid.org/0000-0003-2108-0575>; SangHan Lee: <https://orcid.org/0000-0003-0390-3494>; Yo Han Jeon: <https://orcid.org/0000-0002-0353-7255>; Ji Hyun Park: <https://orcid.org/0000-0002-1534-0070>; Jong Kyu Lee: <https://orcid.org/0000-0002-0492-4417>; Nam Seok Yeo: <https://orcid.org/0000-0001-7254-6414>

Conflicts of Interest

No potential conflict of interest relevant to this article was reported.

References

1. Bart RM, Lau H. Shallow water blackout. Stat Pearls [Internet]. Treasure Island, FL: StatPearls Publishing; 2020 [cited 2022 Jul 13]. Available from: <https://www.ncbi.nlm.nih.gov/books/NBK554620/>.
2. Lindholm P, Lundgren CE. Alveolar gas composition before and after maximal breath-holds in competitive divers. *Undersea Hyperb Med* 2006;33:463-7.
3. Craig AB Jr. Summary of 58 cases of loss of consciousness during underwater swimming and diving. *Med Sci Sports* 1976;8:171-5.
4. Shallow Water Blackout Prevention. How it happens [Internet]. Norcross, GA: Shallow Water Blackout Prevention Inc.; 2022 [cited 2022 Jul 13]. Available from: <http://www.shallowwaterblackoutprevention.org/>.
5. Boyd C, Levy A, McProud T, et al. Fatal and nonfatal drowning outcomes related to dangerous underwater breath-holding behaviors - New York State, 1988-2011. *MMWR Morb Mortal Wkly Rep* 2015;64:518-21.

6. Update: accidental drownings, active component, U.S. Armed Forces, 2005-2014. *MSMR* 2015;22:2-5.
7. Williams VF, Oh GT, Stahlman S. Update: accidental drownings and near drownings, active component, U.S. Armed Forces, 2013-2017. *MSMR* 2018;25:15-9.
8. Park JH, Jeon YH, Choi S, et al. An autopsy report of hypoplastic coronary artery disease incidentally identified in a young man. *Korean J Leg Med* 2021;45:156-8.
9. Smith ET Jr, Davis GJ. Sudden cardiac death associated with hypoplasia of the coronary arteries and conduction system alteration. *Am J Forensic Med Pathol* 1997;18:189-93.